

Expression of MUC4 in Oral Dysplastic Epithelium

Mohammed Abidullah^{1*}, Prashant Nahar², Syed Afroz Ahmed³

¹Department of Oral Pathology, Faculty of Dentistry, Pacific Academy of Higher Education and Research University, Udaipur, Rajasthan, INDIA.

²Department of Oral Medicine and Radiology, Pacific Dental College and Hospital, Airport Road, Debari, Udaipur, Rajasthan, INDIA.

³Department of Oral and Maxillofacial Pathology, Sri Sai College of Dental Surgery, Vikarabad, Hyderabad, Telangana, INDIA.

ABSTRACT

Background: Though various biological markers are available for improving the diagnostic accuracy early detection of disease progression remains a challenging task mainly due to lack of adequate early prognostic marker.

Objectives: To evaluate the immunohistochemical expression of MUC4 in oral epithelial dysplasia and to compare the immuno histochemical expression of MUC4 in Oral Epithelia Dysplasia (OED) and its expression in the normal tissue specimens. **Materials and Methods:** The present retrospective study was undertaken to compare and evaluate the expression of MUC4 in oral epithelial dysplasia and normal. The study comprised of 45 cases of oral epithelial dysplasia and 10 controls. Control specimens were obtained from healthy oral mucosa of individuals undergoing oral surgery for disimpaction of third molars and orthodontic extractions. Serial sections of 3-4 microns thickness were made from the tissue blocks and were stained using immunohistochemical marker MUC4, using an immunoperoxidase technique (ABC method). The semi quantitative analysis of the stained sections was done by light microscopy according to the Immunoreactive Score (IRS) by Remmele and Stegner which evaluated percentage of positive cells and the staining intensity. **Results:** Less than 10% of positive cells were seen in 9 cases of mild dysplasia out of 15 cases and 3 cases showed 10 to 50% of positive cells. Whereas less than

10% of positive cells were seen in 6 cases of moderate dysplasia out of 15 cases and other 9 cases showed 16% and 42% of positive cells respectively. However, in severe dysplasia positive cells percentage increased to 10 to 50% in 10 cases and other cases showed less than 10% respectively.

Conclusion: In the OED group a gradual increase in the staining pattern was observed from mild to moderate to severe dysplasia. Severe dysplasia cases exhibited the staining of entire thickness of epithelium. Thus, it may be concluded that MUC4 plays a very important role and can be reckoned as a handy tool or marker for diagnosis of OED.

Key words: Epithelial dysplasia, Oral squamous cell carcinoma, Mucins, Immunohistochemistry, Leukoplakia, Tobacco.

Correspondence

Dr. Mohammed Abidullah,

Research Scholar, Faculty of Dentistry, Department of Oral Pathology, Pacific Academy of Higher Education and Research University, Udaipur-313003, Rajasthan, INDIA.

Phone no: +91-7993434679

Email: mdabid2512@gmail.com

DOI: 10.5530/ijpi.2019.2.17

INTRODUCTION

Potentially malignant lesions and conditions are the precursor for scores of oral squamous cell carcinomas of oral cavity.¹ Practically all the cancers of oral cavity show evident clinical oral mucosal changes in the configuration of red and white lesion.² The term dysplasia signifies a histopathological changes which can be appreciated in chronic potentially malignant disorders of oral cavity. Dysplasia terminology was brought in by Reagon in 1953 in relation to cells shredded from cervix of uterus.³ Dysplasia turning into malignancy greatly depends on the severity of dysplasia. There are grading of dysplasia based on architectural and cytological criteria based on which most of the diagnosis is made by the oral pathologist taking into account interexaminer and intra examiner variability.^{3,4} Hence studies of potential biomarkers are needed to increase the objectivity.

Various markers have been reviewed till date which includes those associated with cell proliferation, cell differentiation and malignant transformation, related to metastases. Mucin can be exercise as potential biomarkers/indicator in diagnoses of disease and its advancements besides its therapeutics uses.⁵

Mucins are membrane-bound or membrane-secreted glycoproteins expressed in epithelial cells. To date, 21 different mucins have been found in humans. MUC4 is a membrane bound mucin encoded by a gene on chromosome 3q29. Aberrant overexpression of MUC4 has been discovered in many human neoplasms. In tumours, the interaction effects a positive modulation of signalling which leads to growth and constitutive survival.⁶⁻⁸

MUC4 manifestation and adjustment in Glycosylation are associated with the ontogenesis and progression of malignant disease. Thus MUC4 may provide an important target for diagnosis, progression and management of cancers and it also contribute to natural properties of lesions in different ways.^{7,8} Few Studies have revealed the expressions of MUC4 in oral squamous cell carcinoma but the present study is distinctive study that is carried out to analyze expression of MUC4 in oral dysplastic epithelium along with normal tissue, making it first of its kind study.

MATERIALS AND METHODS

The present retrospective study was undertaken to compare and evaluate the expression of MUC4 in oral epithelial dysplasia and normal. The study comprised of 45 cases of oral epithelial dysplasia and 10 controls. It was carried out by retrieving the paraffin embedded tissue blocks of previously diagnosed cases from the past records of Sri Sai College of Dental Surgery, Vikarabad, Hyderabad, Telangana, Department of Oral Pathology, Faculty of Dentistry, Pacific Academy of Higher Education and Research University, Udaipur, Rajasthan and Mehdi Nawaj Jung Institute of Oncology, Hyderabad.

Ethical committee clearance for undergoing the study was obtained from institutional ethical clearance committee.

Inclusion criteria

- 1 Patients with clinically and histopathologically diagnosed OED

2 Normal healthy subjects as controls

Control specimens were obtained from healthy oral mucosa of individuals undergoing oral surgery for disimpaction of third molars and orthodontic extractions. Serial sections of 3-4 microns thickness were made from the tissue blocks and were stained using immunohistochemical marker MUC4, using an immunoperoxidase technique (ABC method).

Evaluation of Staining

MUC4 positive cells were assessed using double light microscope at 10x and 40x. The cell membrane and cytoplasm was stained with brown colour with MUC4. The standard that was used to define MUC4 staining was: brown colour of any of the components. 10 random fields selected and 100 cells were calculated. The positive cells percentage was computed and graded.

Immunohistochemical Scoring

The semi quantitative analysis of the stained sections was done by light microscopy according to the Immunoreactive Score (IRS) by Remmele and Stegner which evaluated percentage of positive cells and the staining intensity (Table 1).⁹

The IRS evaluation was based on modification, which doesn't only measure the visualized grade of colour intensity (staining), but also adds the fraction of cells in each category. Remmele and Sterner suggested that dominant grade of intensity was utilized and the IRS with points from 0-12 were accommodated to an additional 4 point IRS classification. The expression is categorized as low and high based on the IRS scores. Low expression refers to IRS score less than 3, high expression refers to IRS score more than 3.34 for interobserver variability and all the sections that were stained were examined independently by second and third observers with sound knowledge of Remmele and Stegner immunoreactive score.

Statistical analysis

All the analysis was done using SPSS version 20. A *p* value of less than 0.005 was considered statistically significant. Evaluation of MUC4 expression was done in both the control and study groups by using Pearson's chi square test. The interobserver reliability was assessed using kappa coefficient test.

RESULTS

The present study was conducted to compare and evaluate the expression of MUC4 in OED and control group. Interpretation of MUC4 was assessed by two independent observers using kappa coefficient test and the results were submitted to statistical analysis. The inter-observer reliability in recording the MUC4 expression was observed to be 0.634 which

was statistically significant at 0.000 level, implying agreement between the two observers. Hence the results obtained by observer 1 were taken into consideration for further statistical analysis.

MUC4 expressions in controls and study group was evaluated using IRS score, which consecrate a range of 0-12 as a product of multiplication between positive cells proportion score (0-4) and intensity of staining (0-3). The expression is categorized as low and high based on the IRS scores. Low expression refers to IRS score less than 3, high expression refers to IRS score more than 3.

Out of 10 normal mucosa tissue biopsies taken as control group, only one case showed immunostaining of MUC4, where the positive cells appreciated was less than 20%. All the other cases displayed negative staining.

Less than 10% of positive cells were seen in 9 cases of mild dysplasia out of 15 cases and 3 cases showed 10 to 50% of positive cells. Whereas less than 10% of positive cells were seen in 6 cases of moderate dysplasia out of 15 cases and other 9 cases showed 16% and 42 % of positive cells respectively. However, in severe dysplasia positive cells percentage increased to 10 to 50% in 10 cases and other cases showed less than 10% respectively (Table 2 and Figure 1).

Staining intensity was scored following IRS according to which among mild dysplasia cases (15), 6 showed mild staining intensity and 5 cases showed moderate reaction. Whereas 7 cases each of moderate and severe dysplasia showed mild reaction and 6 cases of moderate and 7 cases of severe dysplasia showed moderate reaction.

According to the IRS 4 point score, 10 mild dysplasia cases were graded as negative, 2 cases as mild and 3 were moderate. 5 cases of moderate dysplasia were graded as mild, 4 were graded as moderate and 6 were graded as negatively. In severe dysplasia, 5 cases showed as negative, 3 were mild and 7 were graded as moderate (Table 3).

Table 2: Percentage of positive cells of MUC4 immunostaining among control and study groups.

Group	Sample size	Percentage of positive cells					
		0	1	2	3	4	
Control	10	9	0	1	0	0	
OED	Mild	15	3	9	3	0	0
	Moderate	15	0	6	9	0	0
	Severe	15	0	5	10	0	0

Table 3: IRS score of MUC4 in OED.

Group	N	Final IRS score			
		0-1 = Negative	2-3 = Mild	4-8 = Moderate	9-12 = Strongly positive
Mild OED	15	10	2	3	0
Moderate OED	15	6	5	4	0
Severe OED	15	5	3	7	0

Table 1: IRS and IRS-Classification Scoring Systems.

Percentage of positive cells (0-4)	Intensity of staining (0-3)	IRS Score (Multiplication of A and B)
0=no positive cells	0= no colour reaction	0-1 = negative
1= <10% of positive cells	1= mild reaction	2-3 = mild
2= 10-50% positive cells	2= moderate reaction	4-8 = moderate
3= 51-80% positive cells	3= intense reaction	9-12 = strongly positive
4= >80% positive cells		

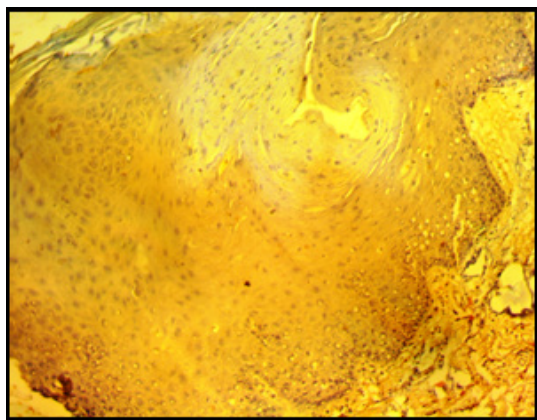
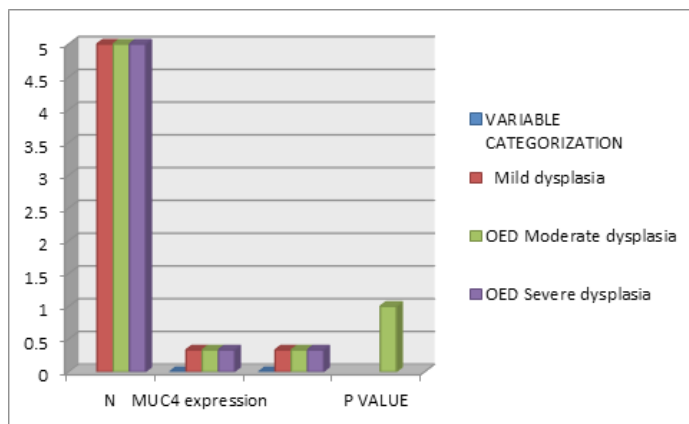


Figure 1: MUC4 Immunostaining in Full Thickness of The Epithelium, Severe Dysplasia (10X).



Graph 1: MUC4 immunostaining in different grades of OED.

When intra-group analysis was done, that is within OED the IRS score for mild, moderate and severe dysplasia were calculated using Pearson's chi square test. The observations made by the chi square test showed that 33.3% of mild, moderate and severe dysplasia cases showed low IRS score and 33.3% showed high IRS score. The p -value of 1.00, which was statistically insignificant, was obtained. (Table 3 and Graph 1).

Evaluation of MUC4 immunostaining in control and study group revealed that in the control group, only 4.3% showed low MUC4 expression and the rest of the cases didn't not reveal any colour change. In the study group, 22.6% and 17.6% of OED cases accounted for low expression and high expression respectively. Immunostaining of MUC4 in control and study groups was evaluated using Pearson's chi square test. A p value of 0.003 was obtained which was statistically significant.

DISCUSSION

Head and neck cancers are heterogeneous group of abnormalities with complicated molecular irregularities. It remains a significant cause of morbidity and accounts for 50% of mortality. Among the carcinomas of head and neck, OSCC contributes for estimated 3% of all malignancies. In recent times its incidence has increased drastically becoming the most common malignant tumor. With respect to the Asian subcontinent, India due to prevalence of harmful habits tobacco chewing, betel quid with lime and areca nut the incidence and prevalence is very high.¹⁻⁴

OSCC begins from a potentially malignant progenitor in many cases followed by emergence of clonal populations associated with accumulative genetic abnormalities and phenotypic progression to invasive malignancy. The premalignant progenitors will show the earliest change that is suggestive of the malignant transformation and becomes squamous cell carcinoma. No authentic method is present which helps in clinically diagnosing the disease advancement towards malignancy. Almost two-thirds of patients are present already in advanced stage of malady at time of diagnosis. Despite improvement in the fields of surgery and radiotherapy, the five year survival rates of HNSCC patients did not increase substantially during the last 20 years. Thus, it provokes a necessity to develop a simple and accurate diagnostic and prognostic marker.^{10,11}

New awareness in relation to mucin molecular biology indicates that some group of mucins additionally are involved in signaling pathways. This help in coordinated responses such as cell proliferation cell differentiation, apoptosis and secretions of cellular products. The MUC- type mucins family (MUC for humans and Muc for other species) are identifies form mucin type glycoprotein cased of the presence of polymorphic central dimain. Distinct profiles of mucin expression are described for different epithelial cell in different organs.¹²

To date twenty one different mucins have been found in humans. In the elite group of mucins family MUC4 is a membrane bound mucin encoded for chromosome 3q29. MUC4 has two sub-units MUC4 alpha and MUC4 beta arising from single transcript and is a non-covalently linked heterodimeric protein complex. MUC4 extracellular component consist enormous 0 Glycosylation domain and a nidogen related domain.¹³

Studies have demonstrated that some tumors express mucins that are not normally native to that organ indicating the role of mucins in the progression of carcinomas in different malignancies. This fact holds true for various potentially malignant and malignant lesions and conditions of pancreas where these mucins are not commonly expressed but they help in carcinogenesis. These observations suggest the role played by MUC4 in the initial stages of Tumorigenesis and get activated during the process of dysplastic transformation to carcinomas. Literature revealed many studies conducted in the past using MUC4 in various tumors like adenocarcinoma of esophagus, crohns disease, gall bladder carcinomas, lung adenocarcinoma, pancreatic ductal adenocarcinoma, epithelial ovarian carcinomas, cancer of prostate cancer of breast and various inflammatory diseases.¹¹⁻¹³

When the results were evaluated statistically significant relation (P value < 0.005) was obtained between the control group and the study group. Out of the ten normal mucosa tissue biopsies which served as controls, mild immunostaining was observed in one case where in the positive cells percentage accounted for less than 20% and the expression was seen in the lower basal layers. All the other samples in the control group displayed negative staining.

Findings of the current study are concordant with the studies conducted by Narasimhan *et al.*¹⁴ Hamada *et al.*⁶ Swartz JM *et al.*¹⁵ MA Macha *et al.*¹⁶ and Yonezawa S *et al.*¹⁷

Narasimhan *et al.*¹⁴ in cases of leukoplakia and OSCC, analyzed that no MUC4 expression was observed in the normal oral mucosa obtained from volunteers with no oral lesions and related oral habits.

Hamada *et al.*⁶ evaluated the MUC4 profile expression in OSCC tissues using immunohistochemistry and demonstrated that not all normal squamous epithelium of the oral cavity expressed MUC4. Only 4% of the patients showed MUC4 positivity in normal oral mucosal epithelium.

Evaluation of different grades of OED revealed a steady increase in the immunostaining of MUC4. Mild dysplasia cases revealed expression restricted to lower basal cell layers and above supra basal layers where as the cases of moderate dysplasia demonstrated staining going up to the granular layer of epithelium. Similar expression pattern was observed with severe dysplasia with all the cases demonstrating entire epithelial thickness staining. Expression and alteration in Glycosylation patterns

of mucins are said to be attached with the ontogenesis and progression of malignant disease. These changes generate many epitopes in the oligosaccharides side chains that are utilized as diagnostic and prognostic markers. Therefore, mucin is utilized as a valuable biological marker to make out the difference between normal and disease condition.^{6,14-17}

CONCLUSION

The present study was conducted to compare the immunohistochemical MUC4 expression in OED and controls. In the OED group a gradual increase in the staining pattern was observed from mild to moderate to severe dysplasia. Severe dysplasia cases exhibited the staining of entire thickness of epithelium. Thus it may be concluded that MUC4 plays a very important role and can be reckoned as a handy tool or marker for diagnosis of OED. To the fullest of our knowledge, this stands to be the first study to be conducted using MUC4 immunohistochemical marker to evaluate the different expression of MUC4 in different grades of OED. However, further studies on a greater sample size should be conducted on a broader aspect to ascertain MUC4 as a useful diagnostic and prognostic tool.

ACKNOWLEDGEMENT

- 1) Faculty of Dentistry, Department of Oral Pathology, Pacific Academy of Higher Education and Research University, Udaipur, Rajasthan.
- 2) Sri Sai College of Dental Surgery, Oral Pathology Department, VIKARABAD, Hyderabad, Telangana.
- 3) Mehdi Nawaj Jung, Institute of Oncology, Hyderabad, Telangana.

CONFLICT OF INTEREST

The authors declare no conflict of interest.

ABBREVIATIONS

OED: Oral Epithelial Dysplasia; **MUC4:** MUCIN 4; **IRS:** Immunoreactive score; **OSCC:** Oral Squamous cell carcinoma; **HNSCC:** Head and neck squamous cell carcinoma.

REFERENCES

1. Croce MV, Rabassa ME, Pereyra A, Eiras AS. Differential expression of MUC1 and carbohydrate antigens in primary and secondary head and neck squamous cell carcinoma. *Head and Neck*. 2008;30(5):647-57.
2. Sarode SC, Sarode GS, Tupkari JV. Oral potentially malignant disorders: A proposal for terminology and definition with review of literature. *J Oral Maxillofac Pathol*. 2014;18(4):77-80.
3. Rastogi V, Puri N, Mishra S, Arora S, Kaur G, Yadav L. An insight to Oral Epithelial dysplasia. *Int J Head Neck Surg*. 2013;4(2):74-82.
4. Markopoulos AK. Current aspects on oral squamous cell carcinoma. *Open Dent J*. 2012;6:126-30.
5. Rachagani S, Torres MP, Moniaux N, Batra SK. Current status of mucins in the diagnosis and therapy of cancer. *Biofactors*. 2009;35(6):509-27.
6. Hamada T, *et al.* MUC4: A novel Prognostic factor of Oral Squamous cell Carcinoma. *Int J Cancer*. 2011;130(8):1768-76.
7. Kermit LC. MUC4 and membrane receptors in cancer. *Mucins and Cancer*. 2013:68-81 Chapter 5 Available from: <http://www.futuremedicine.com/doi/abs/10.2217/fmcb2013.13.69>.
8. Hollingsworth MA, Swanson J. Mucins in cancer: Protection and Control of the cell surface. *Nat Rev Cancer*. 2004;4(1):45-60.
9. Fedchenko N, Reifenrath J. Different approaches for interpretation and Reporting of immunohistochemistry analysis results in the bone tissue- A Review. *Diagn Pathol* 2014;9(1):221.
10. Sadiq H, Gupta P, Singh N, Singh S, Prabhakar I, Thakral J. Various grading systems of the oral epithelial dysplasia: A review. *Int J Adv Health Sci*. 2015;1(11):20-6.
11. Omar EA. The outline of prognosis and new advances in diagnosis of squamous cell carcinoma (OSCC): Review of the literature. *J Oral Oncol*. 2013;1-13.
12. Chauhan SC, *et al.* Aberrant expression of MUC4 in ovarian carcinoma: diagnostic significance alone and in combination with MUC1 and MUC16 (CA125). *Modern Pathol*. 2006;19(10):1386-94.
13. Fedchenko N, Reifenrath J. Different approaches for interpretation and Reporting of immunohistochemistry analysis results in the bone tissue- A Review. *Diagn Pathol*. 2014;9(1):221.
14. Narashiman S, Narasimhan M, Venkatraman G. Expression of Mucin 4 in Leukoplakia and oral squamous cell carcinoma: An immunohistochemical study. *J Oral Maxillofac Pathol*. 2014;18(1):25-31.
15. Swartz MJ, *et al.* MUC4 Expression Increases Progressively in Pancreatic Intraepithelial Neoplasia. *Am J Clin Pathol*. 2002;117(5):791-6.
16. Macha MA, *et al.* MUC4 regulates cellular senescence in head and neck Squamous cell carcinoma through p16/Rb pathway. *Oncogene Advance Online Publication*. 2014;1(11):102.
17. Yonezawa S, Goto M, Yamada M, Highashi M, Nomoto M. Expression profiles of MUC1, MUC2 and MUC4 mucins in human neoplasms and their relationship with biologic behavior. *Proteomics*. 2008;8(16):3329-41.

Cite this article: Abidullah M, Nahar P, Ahmed SA. Expression of MUC4 in Oral Dysplastic Epithelium. *Int. J. Pharm. Investigation*. 2019;9(2):85-8.